

## PennHIP Report

Referring Veterinarian: Dr Heidi Buehner Email: acvh@budget.net	Clinic Name: Allen Creek Veterinary Hospital Clinic Address: 1930 Redwood Ave. Grants Pass, OR 97527 Phone: (541) 476-2233 Fax: (541) 476-0044
--	--

## Patient Information

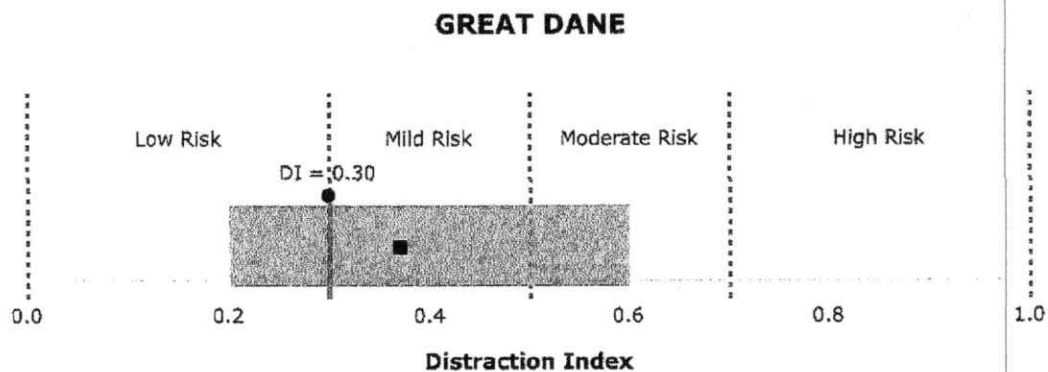
Client: Barlow, Heather Patient Name: Zacchur Barnabas Of Koren House Reg. Name: Zacchur Barnabas Of Koren House PennHIP Num: 166273 Species: Canine Date of Birth: 01 Apr 2021 Sex: Male Date of Study: 09 Dec 2021 Date of Report: 15 Dec 2021	Tattoo Num: Patient ID: 191100002209232 Registration Num: WS73988301 Microchip Num: 191100002209232 Breed: GREAT DANE Age: 8 months Weight: 109.3 lbs/49.6 kgs Date Submitted: 13 Dec 2021
--	---

## Findings

Distraction Index (DI): Right DI = 0.30, Left DI = 0.28. Osteoarthritis (OA): No radiographic evidence of OA for either hip. Cavitation/Other Findings: No cavitation present.
--

## Interpretation

Distraction Index (DI): The laxity ranking is based on the hip with the greater laxity (larger DI). In this case the DI used is 0.30.  
OA Risk Category: The DI is less than or equal to 0.30. This patient is at minimal risk for hip OA.  
Distraction Index Chart:



**BREED STATISTICS:** This interpretation is based on a cross-section of 2090 canine patients of the GREAT DANE breed in the AIS PennHIP database. The gray strip represents the central 90% range of DIs (0.20 - 0.60) for the breed. The breed average DI is 0.37 (solid square). The patient DI is the solid circle (0.30).

*Handwritten signature*